

# Evaluation of the wound healing response post deep dermal heating by fractional RF: INTRAcel

**Un-Cheol Yeo, M.D.**

*S&U Dermatologic Clinic, Seoul, Korea*

**Background and Objectives:** A new device, INTRACEL heating up deep dermis using microneedles of bipolar and monopolar RF in a minimally invasive way; Fractional Radiofrequency Microneedling ("FRM") technology was introduced lately. This study was conducted to see the wound healing response following FRM treatment for both human and porcine skin.

**Study Design and Methods:** A maximum power of 700W RF can be used on bipolar mode to deliver the thermal energy directly into the dermis. 49 microneedles are diffused to 1cm<sup>2</sup> areas on its tip, and those needles are insulated except its distal 0.3mm to avoid the thermal damage on the skin surface when it penetrates into skin. 10 healthy patients and aseptically processed a micro-pig were involved in this clinical trial. Healing responses were observed by the time after FRM treatment at various energy levels. Biopsy was conducted to see the wound healing process immediately after the treatment, 2days, 14days, 28days, and 10 weeks post the treatment. H&E stain and HSP47 stain were conducted to see the changes in inflammatory cell, collagen. Also, the study has conducted RT-PCR with the tissue biopsied from Micro-pig covering 10 weeks to see mRNA change of collagen, Heat Shock Proteins (HSPs), and matrix metalloproteinase (MMPs).

**Results:** No thermal damage was observed on the epidermis and upper dermis except the area the

microneedle electrodes passed, but the collagen was damaged within the reticular dermis. Denatured collagen column was seen through H&E test. 10 weeks later, the observation clearly showed that the pattern of new collagen was granulated on the area of damaged collagen. The increases were observed in 70 days from the FRM treatment in various inflammatory cytokine, HSPs, procollagen 1, procollagen 3, tropoelastin, and fibrillin through RT-PCR test. Seeing the change due to the energy level used for the treatment, the tissue treated with high level energy showed increase of the number of fibroblast, and the collagen reproduction as well as the replacement of damaged collagen.

**Conclusion:** FRM leaves minimal damage by its needle penetration on epidermis and upper dermis, and fractional deep dermal heating is possible in the lower dermis. Such damaged collagen is healed by new collagen being granulated as time passes, and fibroblast proliferation was seen. These conditions are well observed in RT-PCR results, as HSP expressions supporting the production of a new collagen in the tissue stained with HSP antibody. FRM treatment is expected to be good for a tightening, wrinkle reduction, and scar treatment, as it uses various needle depths with the different targets to induce the production of a new collagen and elastin.

**Key words:** bipolar; fractional; micro-needle electrodes; neocollagenesis; ne elastogenesis; deep dermal heating; wound healing

## INTRODUCTION

When ASR (Ablative Skin Resurfacing) was introduced to the aesthetic market, it was effective but it produced patients a lot of pain with a long down time. In contrast, NAR (Non-ablative Rejuvenation)'s side effects and pain was a lot less than ASR, but it provided insufficient efficacy to reach the patient's satisfactory level. Later, fractional laser technology was introduced, but epidermis was burnt and left pigmentation when it tried to deliver the strong energy to deep skin layer. It was obvious as it uses epidermis as the passage of the thermal energy. The new bipolar microneedles RF device was invented to satisfy such demands and needs. This machine has microneedles and it delivers fractional RF energy to induce the thermal damage in the target area of the dermis. Fractional Radiofrequency Microneedling (FRM<sup>TM</sup>) makes thermally and partially injured columns in deep dermis. The dermis in between the thermally injured columns is not wounded. A histology, immunohistochemistry, and molecular biological studies are adopted to observe wound healing process on human body and micro-pig. As results, we found out the fact that FRM treatment induces a strong wound healing response to collagen draw out and elastin remodeling by expressing HSPs and cytokines.

## STUDY DESIGN AND METHODS

A study was carried out total of 70 days with 10 subjects and micro-pig. Patients and micro-pig were treated and observed immediately after, 2 days, 14 days, 28 days, and 10 weeks later. The treatment had done prior to their prescheduled biopsy to capture the temporal evolution of the in

vivo wound healing response.

FRM delivers bipolar RF into dermis by 49 microneedles electrodes of 1.5mm or 0.8mm in their length. Microneedles are inserted into skin at 90 degrees. RF is emitted to dermis after 0.2 seconds post the insertion of microneedles. The delivery times of RF energy are different by the energy level, and the lengths of needles could be chosen among 0.5, 0.8, 1.5, and 2.0mm.

Histological wound healing response was measured to determine deep dermal heating of collagen, elastin, and inflammation. Incision treatments were done for 2 different 2mm biopsies at each time points. The biopsied tissue was set in 10% neutral buffered formalin and moved into paraffin. 10 paraffin or sections were stained with H&E and HSP47 through serial section. Semi-quantitative reverse transcription chain reaction, RT-PCR is used to measure the changes in molecules of remodeling within the dermis post FRM treatment. Electrophoresis was implemented after the RT-PCR. The densitometry analysis using AlphasEase software was used, and  $\beta$ -actin,  $\beta$ -globin glyceraldehyde-3-phosphate dehydrogenase was used as housekeeping genes. Amplicon intensity ratio was estimated by dividing the intensity of housekeeping gene with the intensity value for the gene of interest by the intensity value of for  $\beta$ -actin. The study observed wound healing response in the human body and micro-pig by histology, immunohistochemistry, molecular biology technologies. Research findings indicate that FRM technology enables coagulation necrosis column to be developed in the dermis, and induced dramatic wound healing response, remarkable increase in HSP expression along with dynamical remodeling of collagen and elastin. Thus, this deep dermal fractional heating, FRM technology will be good for facial wrinkles, tightening and scar treatment.

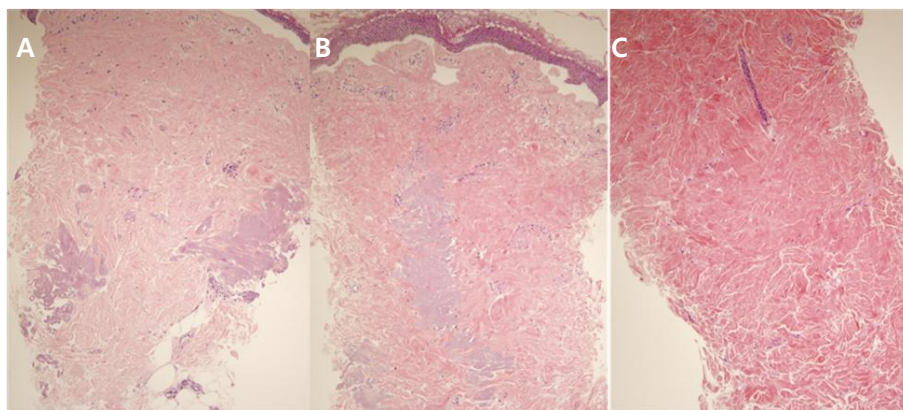


Fig.1. FRM lesions post-treatment. Study adopted in vivo test on human skin immediately, 14 days, 10 weeks post FRM treatment. Observation indicates remodeling in the dermis for 10 weeks. Immediate postoperative shown as “(A)”, “(B)” is postoperative 14days, and “(C)” is postoperative 10weeks. The immediate postoperative shows a clear approval of deep dermal fractional heating without damage on the epidermis, and the density of collagen postoperative 10 weeks more increased than immediate postoperative. Every approval shows dermis remodeling and the progress of new collagen was being created. All images are H&E stained and shown at 2X the original magnification.

## RESULTS AND CONCLUSION

### Deep dermal fractional heating

To see the change in the tissue after FRM treatment, biopsied tissue was stained by H&E immediate, 2days, 14days, 28 days, and 10 weeks post-treatments. Thermally damaged area was detected in reticular dermis immediately after FRM treatment (Fig.1A). Coagulation necrosis part is formed in the deep dermis. Collagen denatured area is disappearing gradually 14 days post-treatment (Fig.1B), and then replaced with a new collagen completely in 70 days post-treatment (Fig.1C). A connection of two coagulation columns with needles tracts on the epidermis were observed in the tissue by serial section just after the treatment (Fig.2).

### Collagen damage is repaired with time.

An infiltration of inflammatory cells was seen to the time points. From postoperative 2 days post treatment slight permeation of inflammatory cells is seen (Fig.3A), partially damaged collagen is absorbed in 14 days and new collagen is seen (Fig.3B). Postoperative 28days, the proliferation of young fibroblast is observed (Fig.3C). Lesion is

being replaced with new collagen in 70 days. HSP47 is expressed in the dermis between 28 days and 70days after the treatment unitedly with the response of inflammatory cells (Fig.4)

The RT-PCR has been taken before the treatment and in the various time points to understand better on the results of molecule events arousing by FRM treatment. Research found that cytokine expression increase for 4 weeks stably but MMPs increased gradually. HSP47 increased over 3 times until 70 days and the expression level of extracellular matrix protein also continued to increase up to 5, 3 times before treatment in tropoelastin and procollagen cases (Table.1)

### Neo-collagenesis is correlated to degree of damage.

This research shows the relationship between a new collagen production and energy level on damage, as the observation shows the increase of the fibroblast proliferation and HSP47 expression at the various energy levels. As the energy level increased, collagen production also increased along with the number of fibroblast (Fig.5). HSP47 also was expressed more in the higher level (Fig.6).

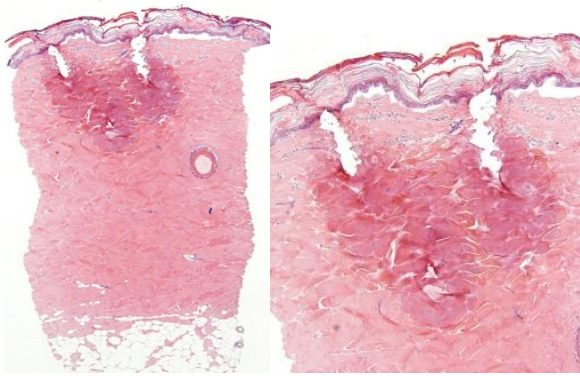


Fig.2. Immediate after FRM treatment. Coagulation columns were made that connected by the two electrodes of bipolar RF plus and minus being connected precisely.

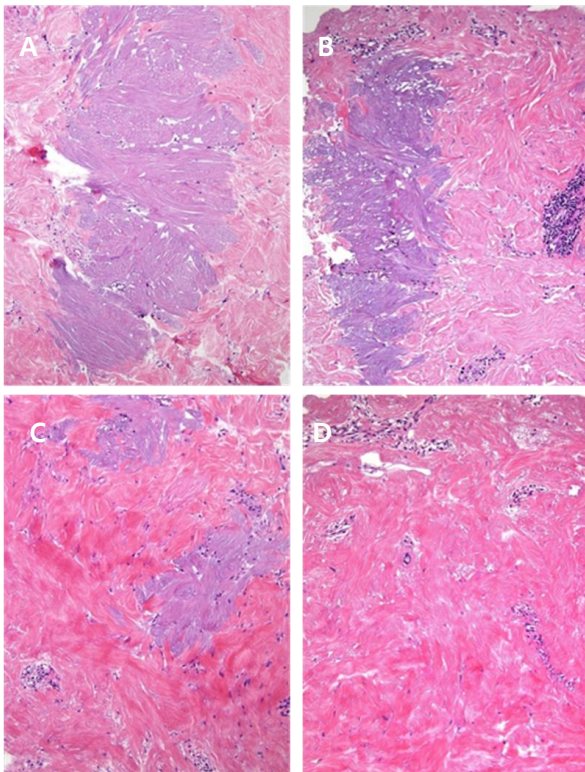


Fig.3. The amorphous degeneration. There is a minimal inflammation in the lesion in 2 days post-treatment (A). Mild infiltrate of chronic inflammatory cells are present in the lesion and adjacent perivascular spaces 14 days post treatment (B). The lesion got absorbed and appeared edematous. The irregular collagen tissue partially replaced to the degenerated lesion In 28 days post treatment (C). The lesion is almost replaced by collagen and was remarkably raised cell density in 70days post treatment (D). The image is seen at the 4X original magnification.

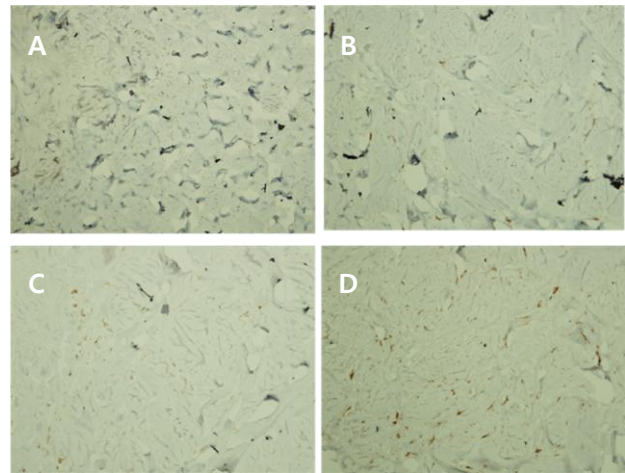


Fig.4. HSP47 responses to FRM treatment. The tissue of micro-pig was stained with HSP47 antibody post FRM treatment. (A) is immediately post treatment, (B) is 14 days post treatment, a minimum of HSP47 expression was detected in the dermis immediately post FRM treatment. HSP47 increases gradually (B), expressed between 28 days (C) and 10 weeks (D), and diffused causing the coagulation necrosis column to be well recovered.

Biopsy showed that the number of the fibroblast didn't increase in the low energy level, and only the hypertrophic response which can get fibers thicker. While fibroblast number increased in the higher energy showing hyperplastic response, an increase in cellularity. The number of cells increases during the wound healing, the effect continued a long time, in general.

#### No change beyond the treatment depth.

HSP47 expression area was observed to see the influence on the extension of collagen remodeling which can be caused by FRM treatment. The comparison of H&E and HSP47 stained tissue shows the occurrences of the strongest expression at the area of collagen denaturation. However, it wasn't expressed any energy level in the deeper area (Fig.7). Therefore, it is better to try FRM to treat the target area when the lesion is in the deep area



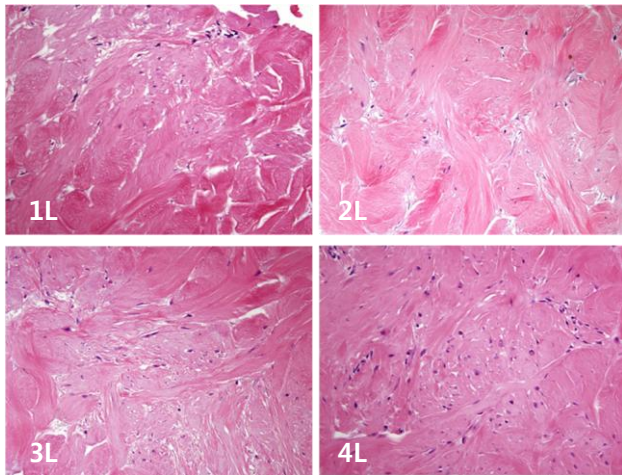


Fig.5. Fig of micro-pig tissue 70 days post FRM treatment. Nucleus and fibers are increased more as energy level get higher.

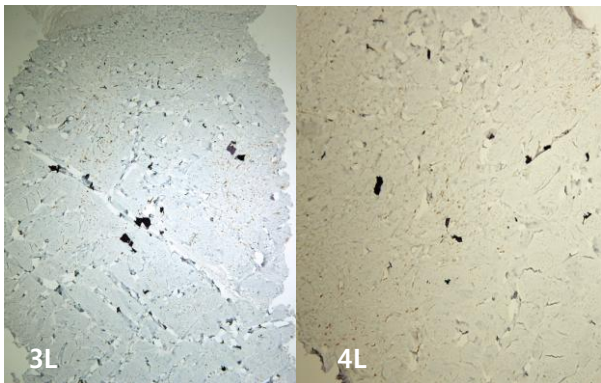


Fig.6. HSP47 response 70 days post FRM treatment. In fact, HSP47 expression is more than doubled in the higher energy level, which means high energy level causes the greater collagen composition.

## DISCUSSION

The 10 weeks observation post FRM treatment has shown dermis remodeling process such as increased production of HSP47 and procollagen, and a full replacement of turning denatured collagen into a new collagen. The study proved the actual volume effect by showing increased production of procollagen and new elastin in the immunohistochemistry and RT-PCR. The result of FRM treatment is better when it operated with a high energy level if it doesn't cause side effect and doesn't make down time long as it produced more

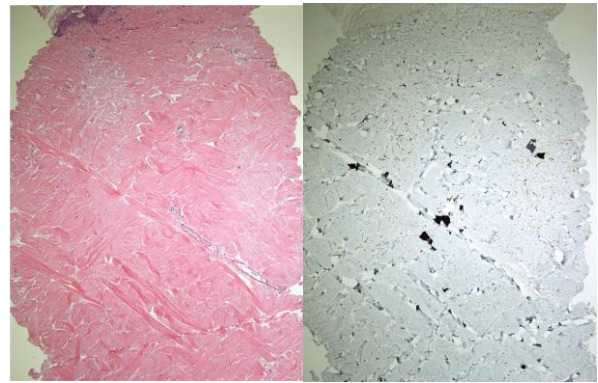
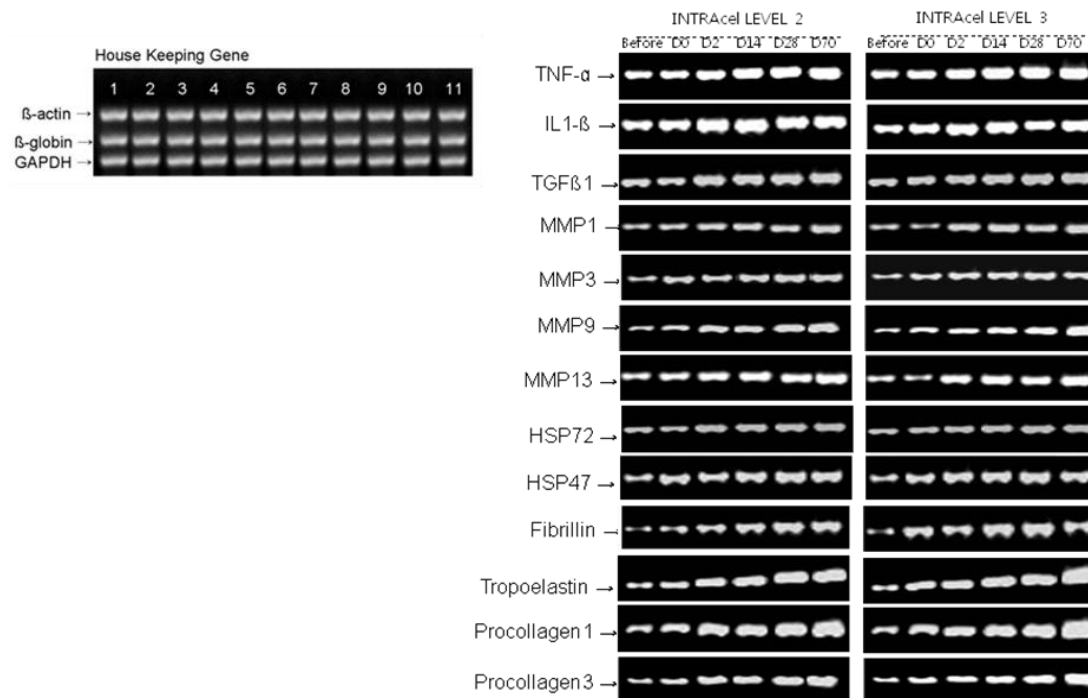


Fig.7. Responses of HSP47 to FRM treatment.

HSP47 is expressed between denatured areas, but never expressed in the deep dermis deeper than the area treated before.

collagen. Through the study, fractional deep dermal heating system on a selected target area is expected to provide good and positive efficacy for a skin tightening, wrinkle reduction, scars and pore treatment.

TABLE 1. Response to FRM Treatment of Various Wound Healing Genes Involved in Dermal Remodeling.



	Baseline	1.5 3L D0	1.5 3L D2	1.5 3L D14	1.5 3L D28	1.5 3L D70
TNF-α	0.32	0.38	0.4	0.4	0.45	0.58
IL-1β	0.26	0.33	0.35	0.35	0.4	0.42
TGF-β1	0.39	0.38	0.42	0.42	0.46	0.58
MMP-1	0.26	0.42	0.36	0.36	0.38	0.37
MMP-3	0.31	0.22	0.39	0.39	0.35	0.46
MMP-9	0.43	0.49	0.87	0.87	1.01	1.13
MMP-13	0.41	0.46	0.67	0.67	0.89	0.81
HSP72	0.62	0.78	0.52	0.52	1.65	1.62
HSP47	0.51	0.62	1.15	1.15	1.42	1.81
Fibrillin	0.84	0.98	1.21	1.21	1.2	1.54
Tropoelastin	0.27	0.36	0.82	0.82	1.12	1.36
Procollagen1	0.67	1.08	1.18	1.18	2.07	2.67
Procollagen 3	0.74	0.92	1.02	1.02	1.32	1.62

Relative expression was calculated as the ratio of the expression level of the gene of interest/expression level of β-actin at each particular time point.